NEET PG 2022

Question Paper

Surgery

(Based on Memory Recall)

Q1. A35 year old female presented to OPD.findings Physical examination are given in the image. Which structure is affected in this condition?



a. Involvement of chest wall
b. Involvement of subdermal lymphatics
c. Involvement of Cooper's ligaments
d. Involvement of connective tissue

Q2. A young male presented with slow growing midline swelling in anterior part of neck. After 6 months, bilateral cervical lymphadenopathy developed. Histopathology slide is given below. All of the following are correct about this condition except:

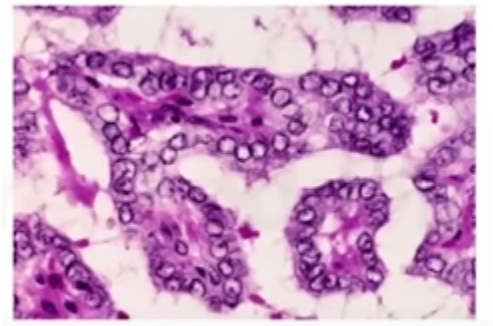

a. Lymphatic spread is seen
b. Specific nuclear pattern on histology
c. Has excellent prognosis

docs.aglasem.com

d. FNAC is not diagnostic

Q3.45 years old female underwent thyroidectomy. On 3" day, she developed peri-oral numbness. Further investigati involves:
a. Free T3,T4
b. Calcium, phosphate and PTH Levels
c. RAI scan
4.73, 74, TSH

Q4. All of the following are the components of MEN-2b except:
a. Parathyroid adenoma
b. Megacolon
c. Marfanoid habitus
d. Mucosal neuroma

Q5. Most common site for intraperitoneal abscess:

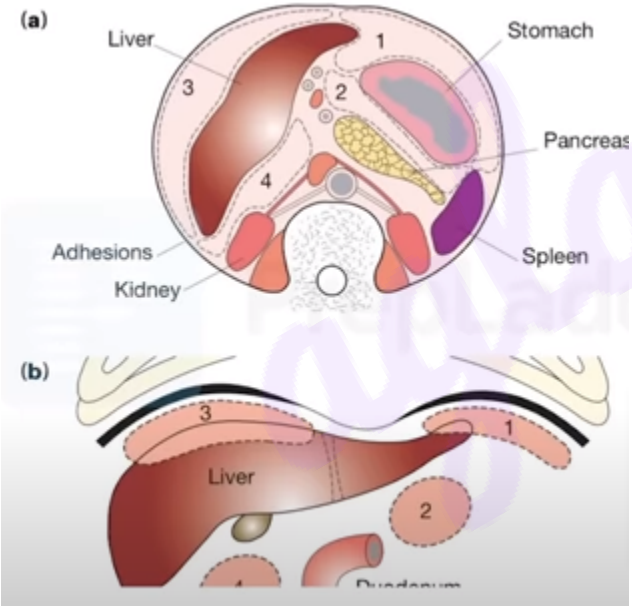

a. 1
b. 2
c. 3
d. 4

docs.aglasem.com

Q6. A 35 years old patient presented with severe abdominal pain and vomiting. His vitals are stable. The radiograph is given below. What is the most effective way to treat this patient?



a. Gastric lavage with cold saline
b. Tracheostomy
c. Chest tube insertion
d. Resuscitation and laparotomy

Q7. An 11-months old was brought to emergency with pain abdomen and multiple episodes of vomiting. On examination, mass was palpable in right lumbar region. Barium enema image is given below. Whatis the diagnosis?



a. Intussusception
b. Volvulus
c. Malrotation

docs.aglasem.com

d. Duodenal atresia

Q8. A patient with long standing hemorrhoids came to the hospital for the routine check-up. On blood investigations, Hb was 7 gm/dL. On peripheral blood smear following findings are seen. What is the most likely diagnosis

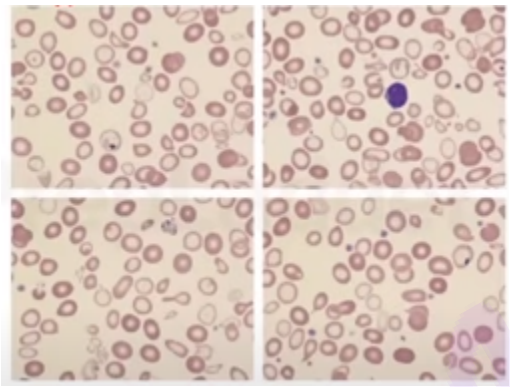

a. Iron deficiency anemia
b. Sideroblastic anemia
c. Megaloblastic anemia
d. Hemolytic anemia

Q9. A 30 years old male presented with recurrent painful perianal nodules on buttocks with serous discharge. The image is given below. What is the most probable diagnosis?



a. Perianal boils
b. Carbuncle
c. Fistula-in-ano
d. Pilondial sinus

docs.aglasem.com

10. A delayed intravenous urogram of the patient is shown below. What is the most likely diagnosis?



a. Putty kidney
b. Staghorn calculus
c. Pelviuretric junction obstruction
d. Renal cyst

Q11. A 6 year old child presented with recurrent UTI. Micturating cystourethrogramam image of the patient is given below. What is the most likely diagnosis



a. Vesicoureteric reflux

docs.aglasem.com

aglasem.com

b. Vesicocolic fistula
c. Urinary bladder hernia
d. Urinary bladder diverticula)

Q12. Identify the correct diagnosis on the basis of given image of newborn baby?



a. Gastroschisis
b. Omphalocele
c. Exstrophy bladder
d. Patent vitellointestinal duct

13. A patient underwent cystoscopy which showed multiple yellow white plaque in the bladder. The histopathological examination shows infiltrated lamina propria layer below. What is the diagnosis?

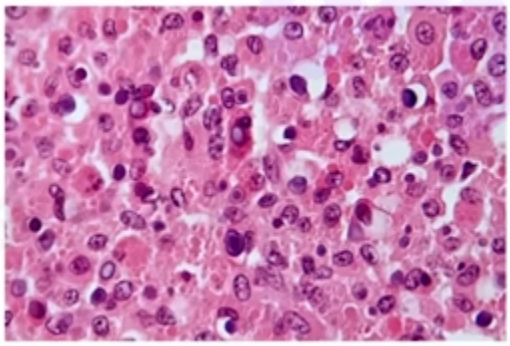

a. Malakoplakia
b. Interstitial cystitis,
c. Acute cystitis
d. Chronic cystitis

docs.aglasem.com

Q14. Route of metastasis of prostate cancer to lumbar vertebrae:

a. Transcoelomic spread

b. Lymphaties

c. Prostatic venous plexus

d. Inferior vesical vein

15. A 30 years old ient with motor vehicl ‘ident presented to the causality. His vitals are stable but he is unable to pass urine. He has blood at the tip of meatus. An RGU was performed as shown below. What is the most likely site of urethral injury?



a. Membranous urethra

b. Penile urethra

c. Bulbar urethra

d. Spongy urethra

Q16. A 55 years nt presented to emergency with scrotal swelling, ecchymosis, fever and serous discharge. Image is given below. What is the most probable diagnosis?



a. Fournier’s gangrene

docs.aglasem.com

aglasem.com

b. Epididymo-orchiditis
c. Torsion testis
d. Carcinoma testis

Q17. A 30 years old male was being investigated for infertility men analysis shows azoospermia. Biopsy image is given below. What is the most probable diagnosis?

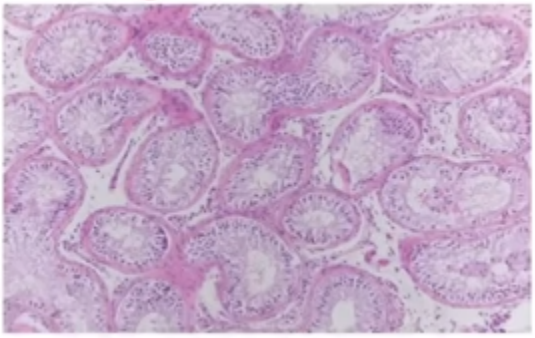

a. Orchitis
b. Sertoli cell only tumor
c. Testicular tumor
d. Non-seminomatous germ cell tumor

18. A patient presented to emergency with claudication of calf muscles, numbness in thigh with impotence. Image showing gangrene of foot is given below. Which artery is involved?



a. Aortic-iliac bifurcation
b. Internal iliac artery
c. Bilateral popliteal artery
d. Femoral artery

docs.aglasem.com

Q19. following surgery for varicose veins, patient started of numbness along the medial aspect of leg. Which is most commonly affected?

a. Superficial peroneal
b. Deep peroneal
c. Saphenous nerve
d. Sural nerve

Q20. A 25 years old patient with history of 'Massive RTA developed dyspnoea and petechial rashes after 3 days of trauma. What is the most likely cause?

a. Massive hemorrhage
b. Fat embolism
c. Thromboembolism
d: Ade embolism

Q21. A 30 years old patient presented to the casualty after a motor vehicle accident. He has bruises on the chest. His 120 beats per minute. BP is 90/60 mmHg and respiratory rate 40/minute. A chest X-ray was performed and shown below. What is the next most appropriate step in the management of this patient?

a. Immediate thoracotomy
b. Pericardiocentesis
c. Pleurodesis
d. Chest drain insertion and drainage

Q22. A 9 years old child was brought to the hospital. There was involvement of half of chest wall and abdomen towards left side, posterior arm and thigh. Calculate the burnt surface area:

a. 5-10%
b. 15-20%
c. 25-30%
d. 35-40%

Q23. A 65 years old patient presented with gradually increasing growth besides the nose near the medial canthus with ulceration. Histopathology image is shown below. What is the most likely diagnosis?

a. BCC
b. SCC
c. Melanoma
d. Nevus

docs.aglasem.com

Q24. A 73 years old male was bed ridden for 15 years. The image of bed sore is given below. What is the grade of bed sore?



a. Grade I
b. Grade II
c. Grade III
d. Grade IV

Q25. A patient with history of chronic alcoholism presented to OPD with whitish patch. What is the most probable diagnosis?



a. Leukoplakia
b. Submucosal fibrosis
c. Erythroplakia
4. Malakoplakia

Q26. A 45 years old patient complaints of recurrent swelling in one side of the neck. She is afraid of eating food as it worsens the swelling. Imagine performed and shown below. What is the most likely diagnosis

docs.aglasem.com

a. Sialolithiasis
b. Penetrating irregular foreign body
c. Isolated osteoma of floor of mouth
d. Cervical lymphadenopathy

Q27. A patient came with swelling near angle of mandible. The swelling was non-tender and was firm. What is your diagnosis?
a. Bezold abscess
b. Osteoma of angle of man
c. Lymphatic enlargement
4. Parotid tumor

Q28. Patient came to OPD with erythematous neck swelling in supraclavicular region. Pulsation were present over the swelling. Image is given below. What is the next best step?
a. Needle biopsy
b. USG Doppler neck
c. CT Angio + Percutaneous intervention
d. Oral antibiotics for 7days

29. Which of the following is most likely to be seen due to rupture of saccular aneurysm in brain?
a. Subdural hemorrhage
b. Subarachnoid hemorrhage
c. Hydrocephalus
d. Intracerebral hemorrhage

30. A 45 years old female presented with galactorrhea. Her urine pregnancy test was negative. MRI brain revealed a large pituitary tumor. Patient refused to undergo surgery for the tumor. Which of the following is the best drug for the treatment of this patient?
a. Bromocriptine
b. Leuprolide
c. Degarelix
d. Cetrorelix

docs.aglasem.com
aglasem.com

31. A patient with stab injury was brought to the emergency Vitals were stable. Iniage is given below. What is next best of management?



a. Further investigation
b. IV fluids
c. Wait and watch after dressing
d. Exploratory laparotomy

32. Green color in triage signifies:
a. Moderate priority
b. High priority
c. Ambulatory
d. Dead

aglasem
docs.aglasem.com
aglasem.com